

Development and Application of a Quick Cleaning and Portable Storage Device for Dislocated Teeth

Chen Xie^{1,†}, Wanyun Lin^{1,2,†}, Junling Guo¹, Yingyu Luo¹, Huijuan Hu¹, Huiqin Yang¹, Zhiteng Deng³, Qinzhi Zhou³, Diwas Sunchuri⁴, Zhu Ling Guo^{1,2}

¹School of Dentistry, Hainan Medical University, Haikou, PR China

²Department of Dentistry, the First Affiliated Hospital of Hainan Medical University, Haikou, PR China

³School of Clinical Medicine, Hainan Medical University, Haikou, PR China

⁴School of International Education, Hainan Medical University, Haikou, PR China

Email address:

604569033@qq.com (Zhu Ling Guo)

† Chen Xie and Wanyun Lin are co-first authors.

To cite this article:

Chen Xie, Wanyun Lin, Junling Guo, Yingyu Luo, Huijuan Hu, Huiqin Yang, Zhiteng Deng, Qinzhi Zhou, Diwas Sunchuri, Zhu Ling Guo. Development and Application of a Quick Cleaning and Portable Storage Device for Dislocated Teeth. *International Journal of Dental Medicine*. Vol. 7, No. 2, 2021, pp. 25-28. doi: 10.11648/j.ijdm.20210702.13

Received: November 10, 2021; **Accepted:** November 21, 2021; **Published:** November 24, 2021

Abstract: Background: The teeth with dental trauma in children are mostly young permanent teeth of school-age children. Once trauma occurs, it will have adverse effects on children's masticatory function, occlusal relationship, beauty, growth and development. Objective: To improve the success rate of replantation of completely dislocated teeth. Methods: Through literature review, we focus on "Tooth Injuries, Complete Dislocation, Replantation" to understand the current rescue measures of dislocated teeth, and conceive a rapid cleaning and portable storage device for dislocated teeth. Results: A device for rapid cleaning and portable preservation of dislocated teeth was successfully designed. Setting the ultraviolet sterilization lamp can play the role of irradiation sterilization and setting the mesh vertical plate can prevent the violent collision of multiple teeth when cleaning. It is possible to divide the storage slot space by setting the baffle, so as to achieve the purpose of classified storage. Conclusion: A rapid cleaning and portable storage device for dropped teeth is described, which solves the problems that the existing rapid cleaning and portable storage device cannot clean teeth uniformly, the cleaning effect is poor, and the cleaned teeth cannot be stored at low temperature.

Keywords: Tooth Injuries, Complete Dislocation, Replantation

1. Introduction

Teeth are the hardest organ of the human body. In addition to the functions of cutting, biting and chewing, they also have the functions of maintaining facial shape and auxiliary pronunciation. The probability of children or adolescents participating in autonomous activities increases gradually. However, the lack of good coordination of movement and lack of the awareness of self-protection is prone to cause tooth trauma, such as tooth fracture, tooth dislocation, tooth prolapse, and so on. Once there is a collision, it often causes several tooth injuries [1]. According to epidemiological data analysis, maxillary incisors are the most common, followed by maxillary lateral incisors, and maxillary teeth are more

common than mandibular teeth [2]. Dental trauma has a great impact on patients' occlusion, aesthetics, emotion and psychology. In addition to pain, severe dental trauma may also affect eating, sleep and social activities [3]. With the progress of science and technology and the development of society, completely dislocated teeth can often be replanted. Dislocated teeth are usually cleaned with phosphate buffer solution (PBS) and then properly preserved for subsequent tooth replantation. However, the existing dislocated teeth preservation device cannot evenly clean the teeth, and cannot preserve the cleaned teeth at low temperature, which has certain limitations. It does not fully realize the practicability of rapid cleaning and portable preservation device, and reducing the success rate of total dislocated teeth replantation. Therefore, it is necessary to

design a rapid cleaning and portable storage device for completely dislocated teeth.

2. Instrument Design

The utility model has the advantages of good cleaning effect and low-temperature preservation by setting a small motor, a battery, a semiconductor refrigeration sheet, a fixed column, a diaphragm, an ultraviolet sterilization lamp, a storage tank, a hollow plate, a material injection pipe, a cleaning and purification tank, a mesh frame, a small ultrasonic generator, a mesh vertical plate, a vent hole and a blanking hole. The left side of the top of the shell is provided with a cleaning and purification tank. The tops of both sides of the inner cavity of the cleaning and purification tank are fixedly connected with support blocks, and the top of the support blocks is provided

with hollow plates. The top of the inner cavity of the hollow plate is communicated with a material injection pipe, and the bottom is provided with a blanking hole. The right side of the inner cavity of the cleaning and purification tank is inlaid with a small motor, and the output end of the small motor runs through the inner cavity of the cleaning and purification tank and is fixedly installed with a mesh frame. A small ultrasonic generator is fixedly installed at the bottom of the inner cavity of the cleaning tank. The bottom of the left side of the inner cavity of the cleaning and purification tank is communicated with a discharge pipe. A controller is fixedly connected at the center of the top of the shell, and a storage slot is arranged on the right side. The bottom of the inner cavity of the storage tank is inlaid with a semiconductor refrigeration sheet, and the inner wall of the storage tank is inlaid with an ultraviolet sterilization lamp.

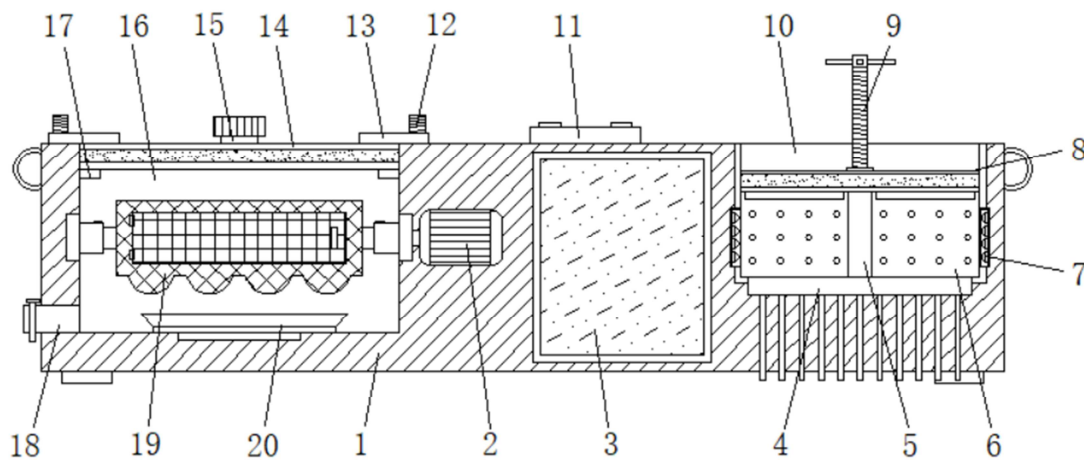


Figure 1. Structural design of quick cleaning and portable storage device for dislocated teeth.

1 case, 2 small motor, 3 battery, 4 semiconductor refrigeration sheet, 5 fixed column, 6 diaphragm, 7 ultraviolet sterilization lamp, 8 pressing plate, 9 screw rod, 10 storage tank, 13 controller, 14 hollow plate, 15 material injection pipe, 16 cleaning and purification tank, 17 support block, 18 discharge pipe, 19 mesh frame, 20 small ultrasonic generator, 21 mesh vertical plate, 22 vent hole, 23 blanking hole.

3. Implementation Mode

The use method of the equipment will be introduced in combination with the attached drawings as follows: When the equipment is ready to use, all parts are in the initial state. First, the mesh door of the mesh frame is opened and the teeth is put into the mesh frame separately. Then, the hollow plate is moved down, so that the bottom of the hollow board contacts with the top of the supporting block, reversing the baffle, and preventing the hollow board from moving up and down at will. An appropriate amount of PBS buffer is added through the injection pipe and the mesh frame is submerged. The small motor and small ultrasonic generator are controlled by the controller to make the mesh frame rotate continuously. At the same time, the small ultrasonic generator sends out ultrasonic wave for vibration, which can achieve the aim of cleaning. After cleaning, the waste liquid is discharged through the discharge pipe. The teeth in the mesh frame are taken out, and classified and placed in the

storage tank. The pressing plate is limited between the bottom of the pressing plate contacts the top of the diaphragm, and then the semiconductor refrigeration sheet is controlled to maintain the temperature at 4°C to realize low-temperature storage. In addition, the ultraviolet sterilization lamp is turned on to sterilize the storage tank before putting the teeth into the storage tank, and the sterilization lamp is turned off before putting the teeth into the storage tank. It should be noted that the crown of tooth should be clamped and the root of the tooth should be avoided touching as much as possible when moving a tooth.

4. Discussion

Trauma refers to a disease in which tooth hard tissue, dental pulp and periodontal tissue are acutely damaged under the action of sudden external mechanical force. It is one of the common causes of emergency in stomatology department. Its clinical manifestations are tooth hard tissue injury, periodontal ligament injury, tooth dislocation, tooth fracture and so on.

Some studies have reported that the incidence of pediatric trauma patients increases when outdoor activities increase in spring and early summer, and some studies have also shown that dental trauma is more likely to occur in winter, which may be related to ethnic characteristics, regional culture, environmental climate, and so on [4, 5]. A survey showed that about 20% of children have suffered tooth trauma [6]. There were more males than females in patients with dental trauma [7]. According to investigation, the incidence rate of dental trauma is increasing [8]. In cases of tooth trauma, the incidence of tooth dislocation is 1% ~ 11% for permanent teeth and 7% ~ 21% for deciduous teeth. It can be seen that tooth dislocation may occur in all dentition stages. It is considered to be one of the most serious and influential types of tooth trauma [9]. The high incidence of permanent dentition trauma is at 10 ~ 12 years old [10]. However, the public awareness rate is not high. A survey of 2215 mothers in Jordan shows that when a 9-year-old child suffers from anterior tooth trauma, only 49% of mothers can answer that the injured tooth is a permanent tooth [11]. Because the root of permanent teeth has been fully developed and the root is in close contact with periodontal tissue. Therefore, the trauma of permanent teeth is often show through the fracture of tooth hard tissue. Because the root of deciduous teeth and young permanent teeth has not been fully developed, so it is easy to be completely dislocation under greater external force. Complete dislocation of teeth means that the teeth are completely separated from the alveolar fossa. As the teeth are subjected to large external force, it is easy to cause periodontal tissue damage and alveolar process fracture at the same time of tooth dislocation. Because children are lively and have a weak sense of self-protection, they are easy to fall and collide with hard objects in the process of sports and playfulness. Therefore, tooth trauma mostly occurs in the maxillary anterior teeth. Moreover, as the loose link between root and periapical tissue in deciduous teeth and young permanent teeth, the incidence rate of tooth dislocation is higher in children and adolescents. The appropriate post-traumatic treatment of teeth is closely related to the prognosis of post-traumatic teeth. The developing apical foramen of young permanent teeth and rich blood supply are conducive to the reconstruction of blood supply and the continuous development of root after tooth injury, which is the basic premise of tooth replantation after dislocation injury of young permanent teeth [12]. Pulp revascularization can induce regeneration of pulp tissue and further development of root. Studies showed that the success rate of revascularization of young permanent teeth is 18% ~ 41% [13].

The success rate of tooth replantation is related to the time of dislocated teeth in vitro, the time and environment of isolated teeth preservation, and whether the apical foramen are closed or the replantation area is polluted [14]. Studies have shown that the success rate of replantation within 15 minutes to 1 hour after complete tooth dislocation can reach 100%. Within 1 hour to 1 day after complete dislocation, the success rate of tooth replantation is 71.4%. In vitro time > 60 min is prone to external root resorption, and the incidence of root bone adhesion increases with the extension of in vitro drying time [15-16]. When replantation is performed one day after

injury, the success rate is only 25%. So, replantation within 15 minutes to 1 hour is the best treatment effect, and the difference is statistically significant [17]. The shorter the isolated time of dislocated teeth, the less the vitality of pulp and periodontal ligament of dislocated teeth is affected, and the possibility of contamination is reduced. Therefore, the higher the success rate of tooth replantation. There are three main healing methods after tooth replantation: periodontal ligament healing, bone adhesion and inflammatory absorption. Periodontal ligament healing refers to the formation of normal periodontal ligament structure between the root and alveolar bone of the replanted tooth. Periodontal ligament healing is the most ideal healing method for tooth replantation, which is limited to those who have been dislocated for a short time, the periodontal ligament tissue is still alive and there is no infection. According to the present study, the probability of periodontal healing was 8.0% ~ 21.4% [18]. The periodontal ligament of completely dislocated teeth begins to degenerate after 30 minutes. If the isolated teeth are stored in a dry environment, it will accelerate the degeneration of periodontal ligament cells. Therefore, the possibility of periodontal ligament healing is higher when the isolated teeth are replanted within 30 minutes. If the tooth is replanted after falling off for 1 hour, almost all the periodontal ligament cells will lose vitality. And the possibility of periodontal ligament healing is very small [19].

A quick cleaning and portable storage device for dislocated teeth can conduct heat and dissipate heat to a semiconductor refrigeration sheet by setting a heat conducting sheet. The ultraviolet sterilization lamp plays the role of irradiation sterilization. The push rod is used to drive the screw rod to rotate. The screw and baffle can be used together to limit the top of the hollow plate. The mesh vertical plate is to prevent multiple teeth from violent collision during cleaning. The air flow can be evenly circulated by vent hole. The partition plate can divide the storage slot space, so as to achieve the purpose of classified storage. The device solves the problems that the many rapid cleaning and portable storage devices cannot evenly clean the teeth, poorly cleaning effect, and the cleaned teeth cannot be preserved at a low temperature environment. The device has the advantages of fast cleaning and portable storage.

5. Conclusion

In conclusion, it is necessary for completely dislocated teeth to keep in a humid environment, clean the pollutants, and then reimplant them into the alveolar fossa, which is conducive to the long-term retention of replanted teeth in the mouth and continuous function. Therefore, a rapid cleaning and preservation device for dislocated teeth is particularly important.

Fund

This research was funded by High-level Talents Project of Hainan Natural Science Foundation (821RC687), Research

Project of Education Department of Hainan Province (Hnjg2021-60), Course Construction Project of Hainan Medical University (HYJW202117), Educational Scientific Research of Hainan Medical University (HYYB202014), Research Project of Hainan Provincial Humanities Medical Research Base (QRYZH201811 (YB), Innovative Entrepreneurial Training Program of Hainan Medical University (X202011810020).

References

- [1] Yi You, Peicheng Huang. Clinical Analysis of 210 Cases of Dental Trauma in Children [J]. Journal of Chinese Physician, 2020, 22 (03): 426-428.
- [2] Qian H. Risk factors and prevention strategies of traumatic dental injury in children [J]. J Dent Prev Treat, 2017, 25 (8): 477-481.
- [3] Arhakis A, Athanasiadou E, Vlachou C. Social and psychological aspects of dental trauma, behavior management of young patients who have suffered dental trauma [J]. Open Dent J, 2017, 11 (1): 41-7.
- [4] Kim C, Choi E, Park KM, et al. Characteristics of patients who visit the dental emergency room in a dental college hospital [J]. J Dent Anesth Pain Med, 2019, 19 (1): 21-27.
- [5] Llarena RM, Acosta AV, Garcia-Godoy F. Traumatic injuries to primary teeth in Mexico City children [J]. Dent Traumatol, 2010, 8 (5): 213-214.
- [6] Ghadimi S, Seraj B, Keshavarz H, et al. The effect of using an educational poster on elementary school health teachers' knowledge of emergency management of traumatic dental injuries [J]. J Dent (Tehran), 2014, 11 (6): 620-628.
- [7] Dua R, Sharma S. Prevalence, causes, and correlates of traumatic dental injuries among seven-to-twelve-year-old school children in Dera Bassi [J]. Contemp Clin Dent, 2012, 3 (1): 38-41.
- [8] Panzarini SR, Gulinelli JL, Poi WR, et al. Treatment of root surface in delayed tooth replantation: a review of literature [J]. Dent Traumatol, 2008, 24 (3): 277-282.
- [9] Gopikrishna V, Thomas T, Kan daswamy D. A quantitative analysis of coconut water: a new Storage media for avulsed teeth [J]. Oral Surg Oral Med Oral Pathol Oral Radiol Endod, 2008, 105 (2): 61-65.
- [10] Moradi MN, Zohrehei H, Darvish A, et al. Continued root formation after delayed replantation of an avulsed immature permanent tooth [J]. Case Rep Dent, 2014, 2014: 832637.
- [11] Suhad H. Knowledge of Jordanian mothers with regards to emergency management of dental trauma [J]. Dental Traumatology, 2010, 22 (6): 291-295.
- [12] Yuan PENG. The factors affecting the reimplantation of young permanent teeth with traumatic dislocation [J]. Journal of Henan University (Medical Science), 2018, 37 (02): 137-139.
- [13] Yanpiset K, Trope M. Pulp revascularization of replanted immature dog teeth after different treatment methods [J]. Endod Dent Traumatol, 2000, 16 (5): 211-217.
- [14] Khinda VI, Kaur G, Brar GS, et al. Clinical and Practical Implications of Storage Media used for Tooth Avulsion [J]. International Journal of Clinical Pediatric Dentistry, 2017, 10 (2): 158-165.
- [15] Roskamp L, Trevilatto PC, Souza CM, et al. Analysis of the association of clinical factors and IL-4 gene polymorphisms with root resorption in avulsed teeth after 1 year of replantation [J]. Int Endod J, 2018, 51 (1): 12-19.
- [16] Lauridsen E, Andreasen JO, Bouaziz O, et al. Risk of ankylosis of 400 avulsed and replanted human teeth in relation to length of dry storage: A re- evaluation of a long- term clinical study [J]. Dent Traumatol, 2020, 36 (2): 108-116.
- [17] Xin ZHANG, Hai-Tao LU. Analysis on the clinical efficacy of 61 cases of replantation for complete dislocation of young permanent teeth [J]. Modern Chinese Doctor, 2020, 58 (24): 74-76+80.
- [18] Wang G, Wang C, Qin M. A retrospective study of survival of 196 replanted permanent teeth in children [J]. Dent Traumatol, 2019, 35 (4-5): 251-258.
- [19] Fouad AF, Abbott PV, Tsilingaridis G, et al. International Association of Dental Traumatology guidelines for the management of traumatic dental injuries: 2. Avulsion of permanent teeth [J]. Dent Traumatol, 2020, 36 (4): 331-342.